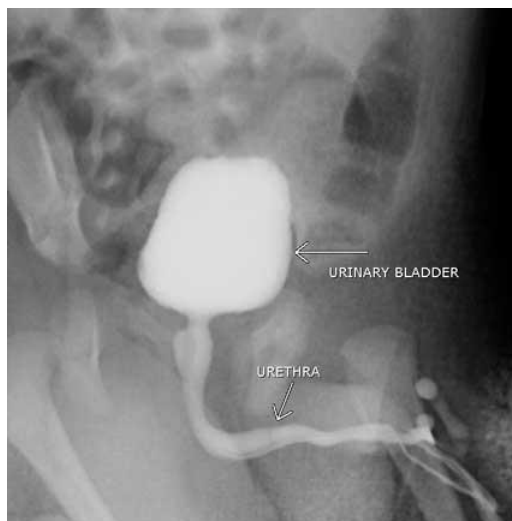


## Pediatric Voiding Cystourethrogram

- ***What is a Pediatric Voiding Cystourethrogram?***
- ***What are some common uses of Pediatric Voiding Cystourethrogram?***
- ***How should my child be prepared for the Pediatric Voiding Cystourethrogram?***
- ***How does the Pediatric Voiding Cystourethrogram procedure work?***
- ***How is the Pediatric Voiding Cystourethrogram performed?***
- ***What will my child experience during his or her Pediatric Voiding Cystourethrogram?***
- ***What are the benefits vs. risks of Pediatric Voiding Cystourethrogram?***
- ***What are the limitations of a Pediatric Voiding Cystourethrogram?***

### *What is a Pediatric Voiding Cystourethrogram?*

A voiding cystourethrogram (VCUG) is an x-ray examination of the bladder and lower urinary tract. A catheter is inserted through the urethra, the urinary bladder is filled with a water-soluble contrast material, and the catheter is withdrawn. Several x-ray images of the bladder and urethra are captured as the patient empties the bladder. These images allow radiologists to diagnose any abnormalities in the flow of urine through the body.



*Sample image: Voiding cystourethrogram. Oblique view of a young male during voiding.*

### *What are some common uses of Pediatric Voiding Cystourethrogram?*

In children, a voiding cystourethrogram is often recommended after a urinary tract infection to check for a condition known as vesicoureteral (VU) reflux.

Urine is produced in the kidneys and flows through the ureters into the bladder. A valve mechanism prevents urine from backing up into the kidneys as the bladder gets full. Urine leaves the bladder through the urethra and is eliminated from the body during urination.

In some children an abnormality in the valve or the ureters allows urine to flow backwards into the ureters, referred to as VU reflux. In mild cases urine backs up into the lower ureter. In severe cases it can back up into a swollen kidney.

Usually children with this condition are born with it. Other causes can include blockage to the bladder, abnormal urination with very high pressure within the bladder, incomplete emptying of the bladder, or urinary tract infections. Reflux is commonly associated with urinary tract infections, occurring in about 40 percent of newborns and infants, and 25 percent of older children. Urinary tract infection may be the only symptom of the problem.

#### *How should my child be prepared for the Pediatric Voiding Cystourethrogram?*

Because a voiding cystourethrogram (VCUG) is an x-ray procedure, metal objects can affect the image, so avoid dressing your child in clothing with snaps or zippers. Replace metal diaper pins with adhesive tape. No other special preparation is required. Sedation is rarely needed and is not desirable because it is important to be able to watch the child urinate during the examination.

#### *How does the Pediatric Voiding Cystourethrogram procedure work?*

Very small, controlled amounts of x-ray radiation are passed through the body. Different tissues—such as bone, blood vessels, muscles and other soft tissues—absorb x-ray radiation at different rates. When a special film plate is exposed to the x-rays that pass through the patient, an image of the inside of the body is captured. The tissues of the urinary tract are similar in density, so a contrast material is used to help produce clearer images.

#### *How is the Pediatric Voiding Cystourethrogram performed?*

The technologist begins by positioning your child on the table. Infants and young children may be wrapped tightly in a blanket or other restraint to help them lie still during the imaging.

One or more images are usually captured before the contrast material is introduced. Your child will be cleaned with special soap and a small, sterile tube is placed through the urethra into the bladder. The tube in the bladder is then connected to a bottle of a special contrast material that is dripped by gravity until the bladder is filled. The radiologist and/or the technologist watch a monitor while the bladder is filling to see if any of the liquid goes backward into one or both ureters.

After the bladder is filled, the catheter is removed and a series of images are captured as your child empties his or her bladder. After your child has voided completely, a final image is taken to see how well the bladder empties.

### *What will my child experience during his or her Pediatric Voiding Cystourethrogram?*

A voiding cystourethrogram is painless, though young children can be frightened when they are tightly wrapped and unable to move. Before the catheter is inserted, your child's genital area is scrubbed and prepared with sterile materials, which may feel cold because of the antiseptic used. Inserting the catheter and filling the bladder with the liquid contrast material causes no pain but some children may experience mild discomfort.

A parent is sometimes allowed to stay in the room to alleviate fear but will be required to wear a lead apron to prevent radiation exposure.

### *What are the benefits vs. risks of Pediatric Voiding Cystourethrogram?*

#### Benefits

- Voiding cystourethrogram (VCUG) images provide valuable, detailed information to assist physicians in diagnosing and treating urinary tract conditions to prevent kidney damage.
- Imaging of the urinary tract with VCUG is a minimally invasive procedure with rare complications.
- A VCUG can often provide enough information to direct treatment with medication and avoid more invasive surgical procedures.
- The imaging process is fast, painless and less expensive than alternatives such as computed tomography (CT) and magnetic resonance imaging (MRI).

## Risks

- X-rays are a type of electromagnetic radiation, are invisible, and create no sensation when they pass through the body. Modern x-ray techniques use only a fraction of the x-ray dose required in the early days of radiology.
- Special care is taken during x-ray examinations to ensure maximum safety for the patient by restricting the x-ray exposure to only the part of the body being examined.
- For a child that is 5-10 years old, the effective radiation dose from this procedure is about 1.6 mSv, which is about the same as the average person receives from natural background radiation in 6 months. For an infant, the effective radiation dose from this procedure is about 0.8 mSv, which is about the same as the average person receives from background radiation in 3 months. See the Safety page for more information about radiation dose.

Radiation risks are further minimized by:

- The use of high-speed x-ray film that does not require much radiation to produce an optimal image.
- Technique standards established by national and international guidelines that have been designed and are continually reviewed by national and international radiology protection councils.
- Modern, state-of-the-art x-ray systems that have very tightly controlled x-ray beams with significant filtration and x-ray dose control methods. Thus scatter or stray radiation is minimized and those parts of a patient's body that are not being imaged receive minimal exposure.

### *What are the limitations of a Pediatric Voiding Cystourethrogram?*

A voiding cystourethrogram cannot evaluate obstruction of flow of urine from the kidneys. Additional examinations are needed if obstruction is suspected.

A voiding cystourethrogram should not be performed while an active, untreated urinary tract infection is present.